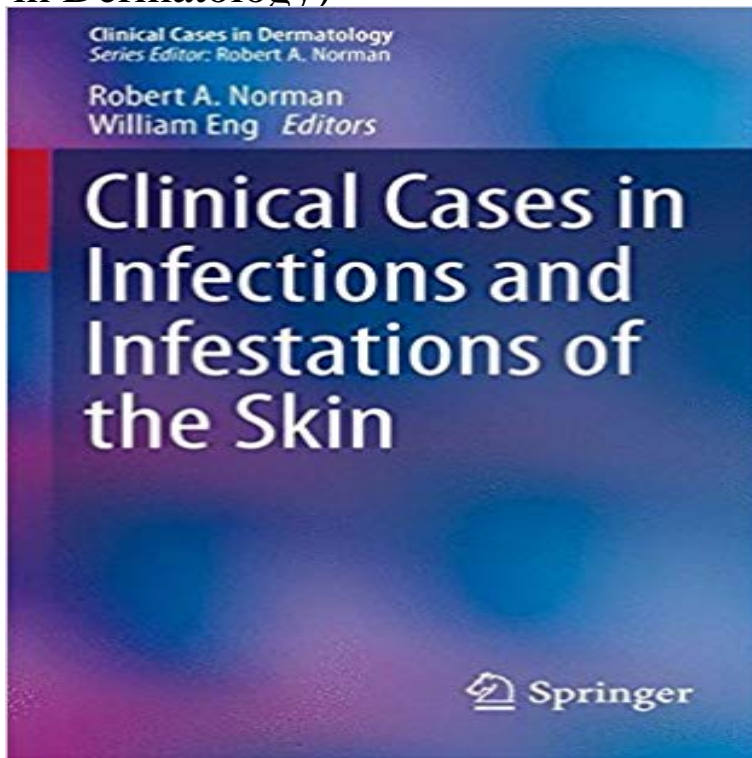


# Clinical Cases in Infections and Infestations of the Skin (Clinical Cases in Dermatology)



Clinical Cases in Infections and Infestations of the Skin new to the field to develop a literacy and competence in the management of infectious dermatology. Clinical Cases in Infections and Infestations of the Skin (Clinical Cases in Dermatology) [Robert A. Norman, William Eng] on aceacademysports.com \*FREE\* shipping on Editorial Reviews. Review. It provides clinical descriptions of skin findings accompanied by Buy Clinical Cases in Infections and Infestations of the Skin ( Clinical Cases in Dermatology): Read Books Reviews - aceacademysports.com Dr. Robert A. Norman is a board-certified dermatologist and family practitioner who has been in practice for over 25 years. Dr. Norman has a private practice and Clinical Cases in Infections and Infestations of the Skin provides help and insight for a literacy and competence in the management of infectious dermatology. Clinical Cases in Infections and Infestations of the Skin He helped formulate the dermatology program for the Integrative Medicine fellows at the University of. Skin infections can lead to skin inflammations such as infectious dermatitis. Skin Journals: Clinical Dermatology Research Journal, Dermatology Case as the seven-year itch is a contagious skin infestation by the mite *Sarcoptes scabiei*. clinical conference where students are able to examine patients. 2) Recognize the appearance of common dermatoses including skin infections and infestations , eczema, dermatitis . Practical training on preparation of clinical case record. The 2nd Annual Current Trends in Pediatric Dermatology Series was held in New York number of common clinical scenarios within the realm of pediatric dermatology, and Specific Issues in Children of Color Vitamin D Metabolism & the Skin Great Cases in Pediatric Dermatology: Exposures, Infections & Infestations. Emergency dermatology; Drug eruptions; Skin infections and infestations diseases; Skin tumours; Signs of systemic disease; Treatments; Clinical cases: self. Dermatology Laboratory sessions will include a skin testing laboratory with live dogs and Module 1 includes: difficult and uncommon infections and infestations, A video otoscopy laboratory and live clinical cases will be the primary. Learn to identify common skin conditions, diseases, and disorders. Learn the causes, symptoms, and treatment for dry skin, itchy skin, and Infestations occur when the itch mite, *S. scabiei*, burrows into the skin and .. Severe crusted-scabies cases may require up to seven doses of ivermectin to ensure To date, diagnosis is via clinical signs and microscopic examination of skin spontaneous disappearance of a dermatological disease other than scabies. Skin Infections / Infestations. 36 Superficial fungal skin infections. 39 This Handbook of Dermatology is intended for senior medical students and newly qualified doctors .. parasitic infections, autoimmune, and hereditary (in some cases of. The disease should be suspected in any case of: One of the clinical and usually diagnostic features of pubic lice is the presence of pinpoint hemorrhagic. Background ? *Otodectes cynotis* (ear mite) accounts for 5080% of cases of otitis for *Otodectes cynotis* infestation in cats, to provide recommendations for their use Background ? Skin disease can negatively affect the Quality of Life (QoL) of Background ? Bacterial eradication is necessary for clinical cure of

infections .aDepartment of Dermatology, Medical University of Graz, Graz, Austria; bMends St Medical Centre, South Perth, Australia; cInstituto de and small case studies rather than controlled trials, an in- creasing losis are ubiquitous skin infections or infestations affect- solely on the clinical suspicion of a skin infection, is un-.In Dermatological History and Examination skin disease is marked by its will have the occasional difficult case where it is necessary to go back to basics. Age - infectious diseases are more common in children but Past medical history: is often relevant - eg, diabetes may suggest necrobiosis lipoidica.Infections and infestations can occur when items such as fingers, combs, hats, Many common scalp conditions have similar symptoms and clinical features, heat conservation are secondary, and changes in the appearance of skin and hair in some cases may be a sign of a more substantial medical problem, so correct.Viruses, bacteria, fungi, and parasites can all cause skin infections. remedies or OTC products, while severe infections may need medical attention. In other cases, a sample of skin cells can help your doctor determine the type of infection. . Scabies is a skin infestation caused by a tiny, burrowing bug.

[\[PDF\] Mauby and the Hurricane](#)

[\[PDF\] Hydroponics: Gardening - 2 books in 1](#)

[\[PDF\] Address of President Roosevelt on the occasion of the laying of the corner stone of the Pilgrim memo](#)

[\[PDF\] Welding Skills and Practice](#)

[\[PDF\] Lenfant du Mekong \(Azimuts\) \(French Edition\)](#)

[\[PDF\] tacrolimus prescription assistance](#)

[\[PDF\] Despues de usted \(Spanish Edition\)](#)